

UT Medical Center
Sarcoma Outcomes Study
(1997-2007)

James M. Lewis, MD
Assistant Professor
UT Department of Surgery
Division of Surgical Oncology

UT MEDICAL CENTER
CANCER INSTITUTE

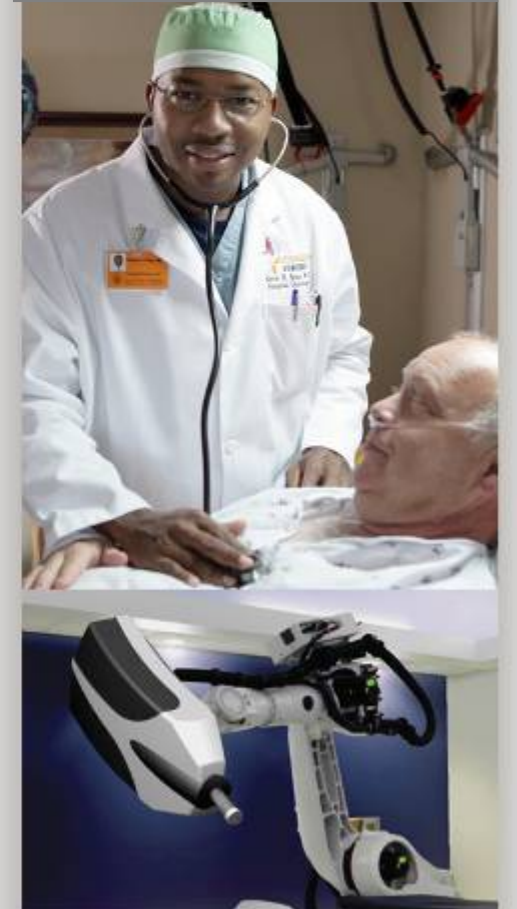

Figure 1: Demonstrates an abbreviated list of progenitor tissue, its benign tumor, and its malignant counter part.

<u>Tissue Type</u>	<u>Benign Tumor</u>	<u>Malignant Tumor</u>
Fat	Lipoma	Liposarcoma
Muscle	Rhabdomyoma	Rhabdomyosarcoma
Muscle	Leiomyoma	Leiomyosarcoma
Nerve	Neurofibroma	Neurofibrosarcoma
Joint tissue	Nodular Tenosynovitis	Synovial Sarcoma
Fibrous tissue	Fibromatosis	Fibrosarcoma
Vessel	Hemangioma	Angiosarcoma

Figure 2: Imaging reveled a 7.7 x 20 x 8.4 cm mass that compressed critical neurovascular structures and rested against bone.

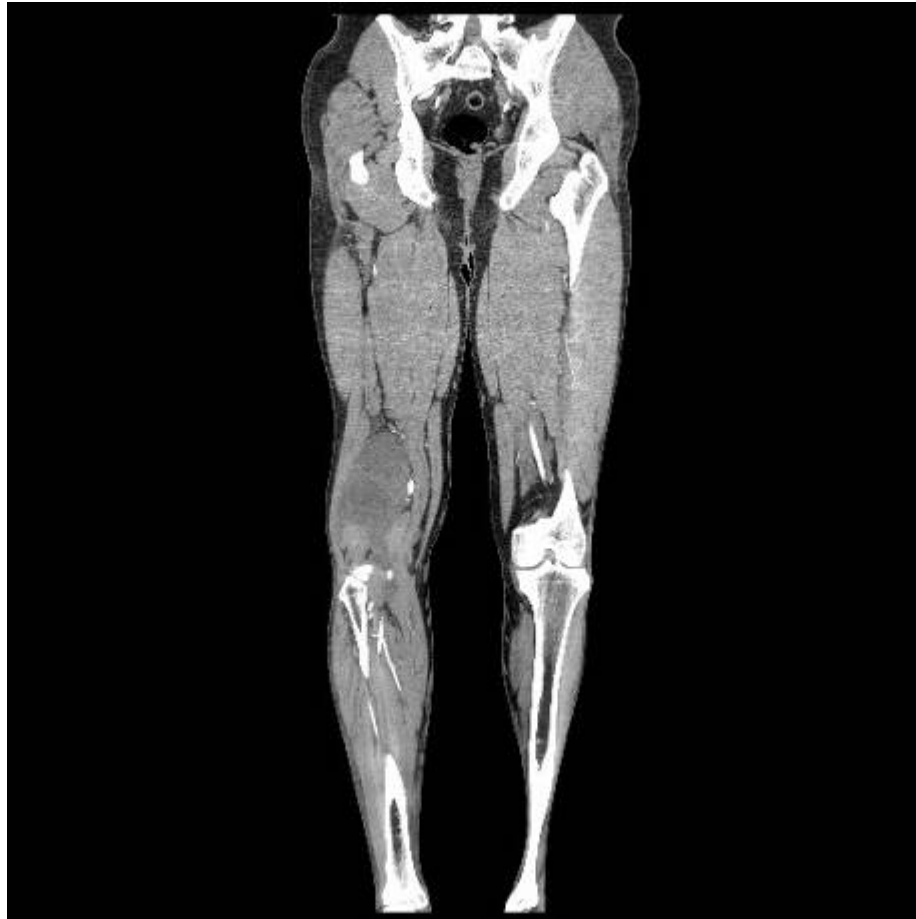

Figure 3: Large sarcoma with the neurovascular structures abutting the tumor

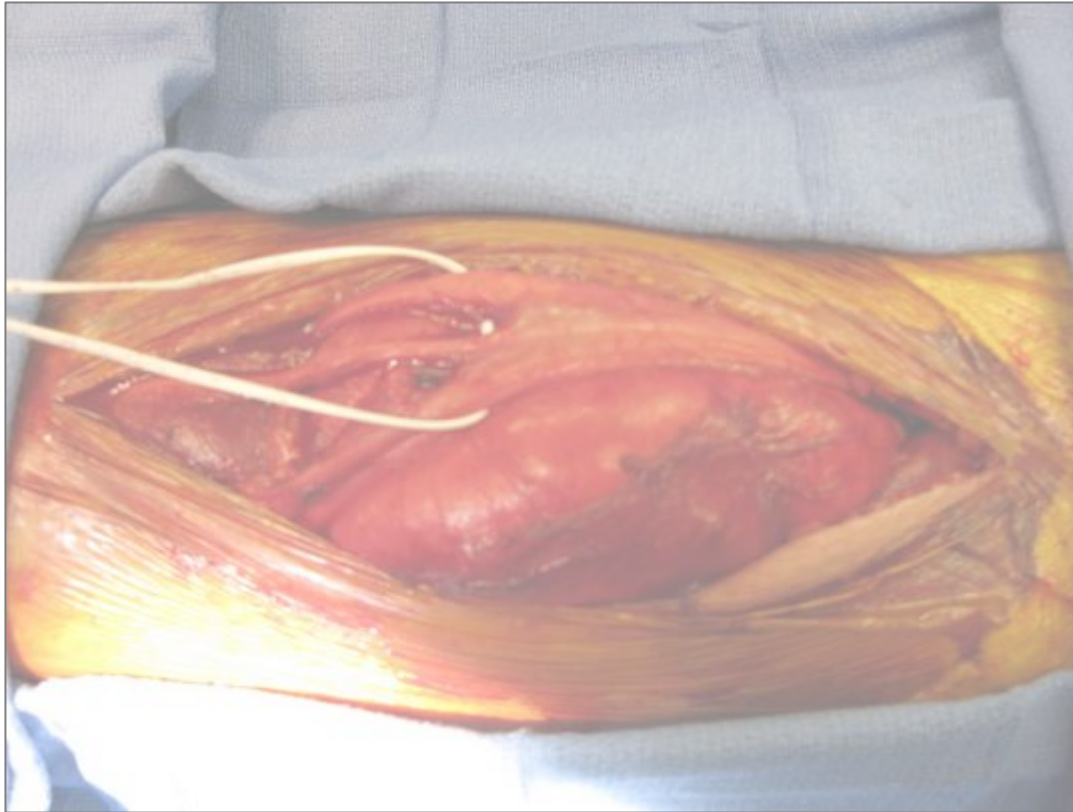


Figure 4: Resected tumor bed with preservation of neurovascular structures

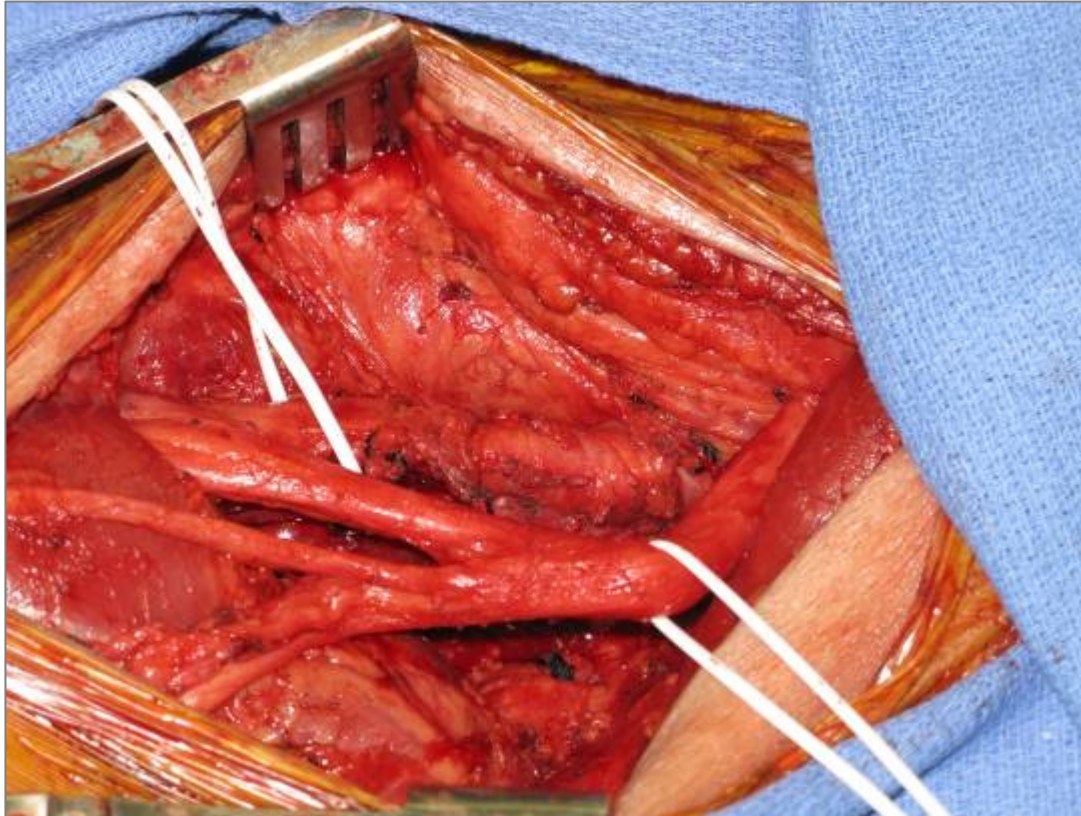


Figure 5: The resected sarcoma

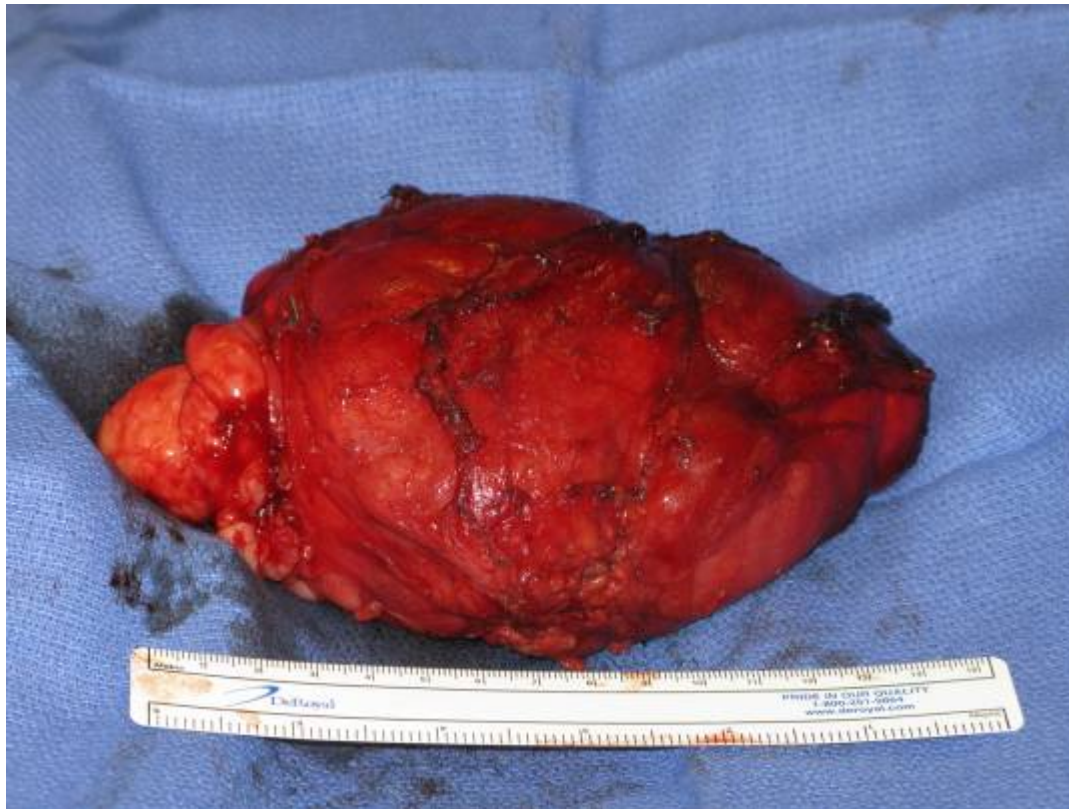

Figure 6:

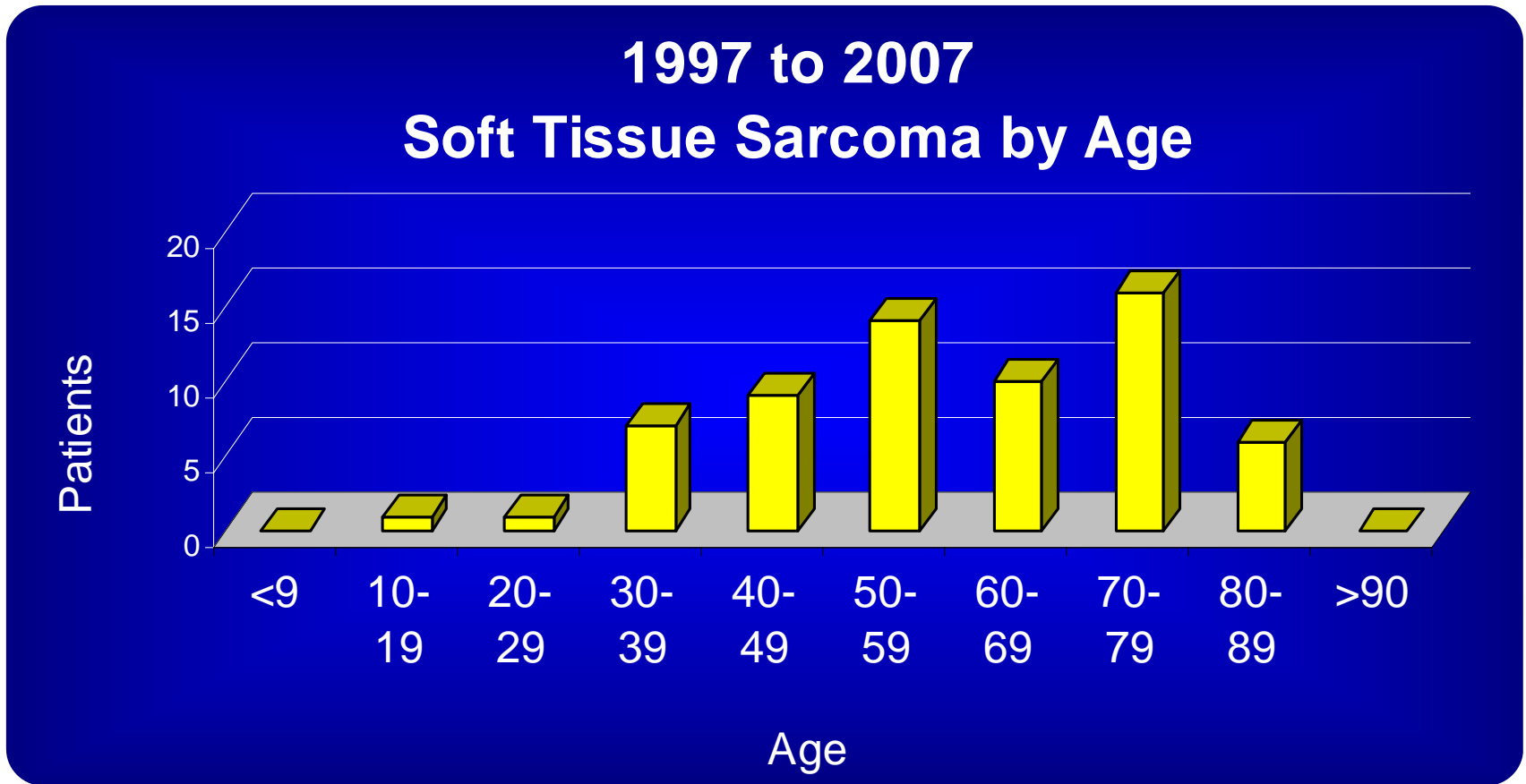


Figure 7:

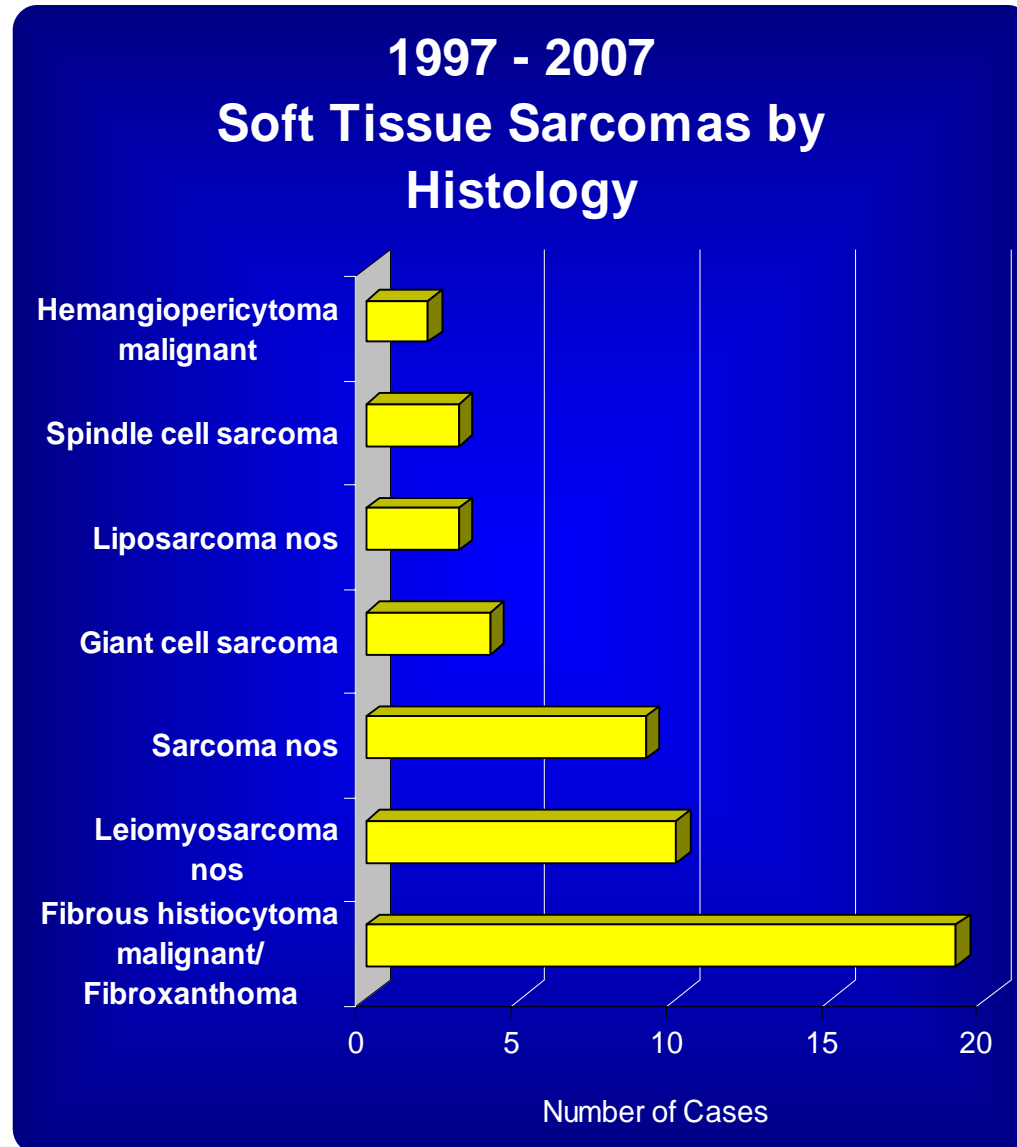


Figure 8:

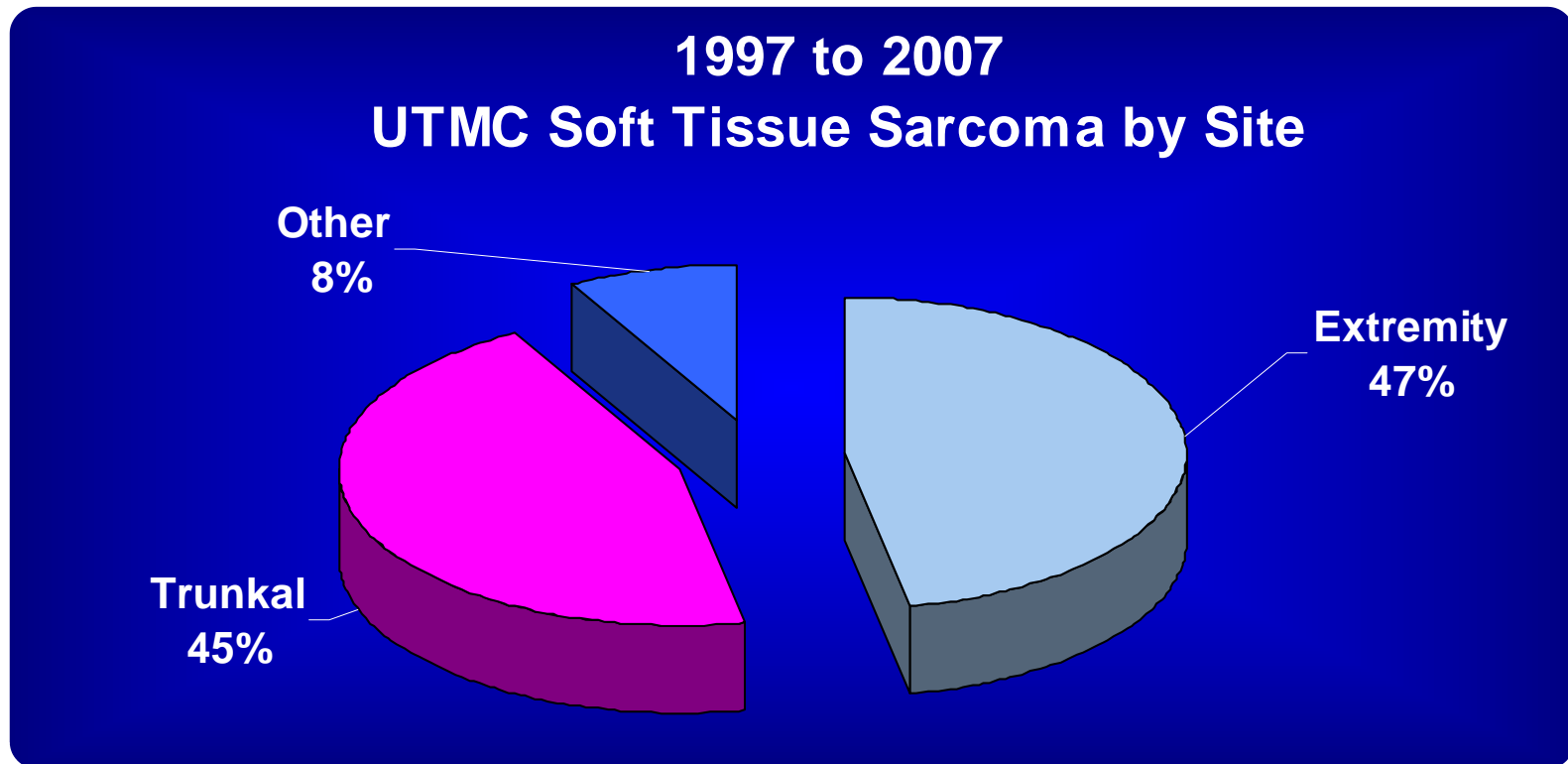


Figure 9:

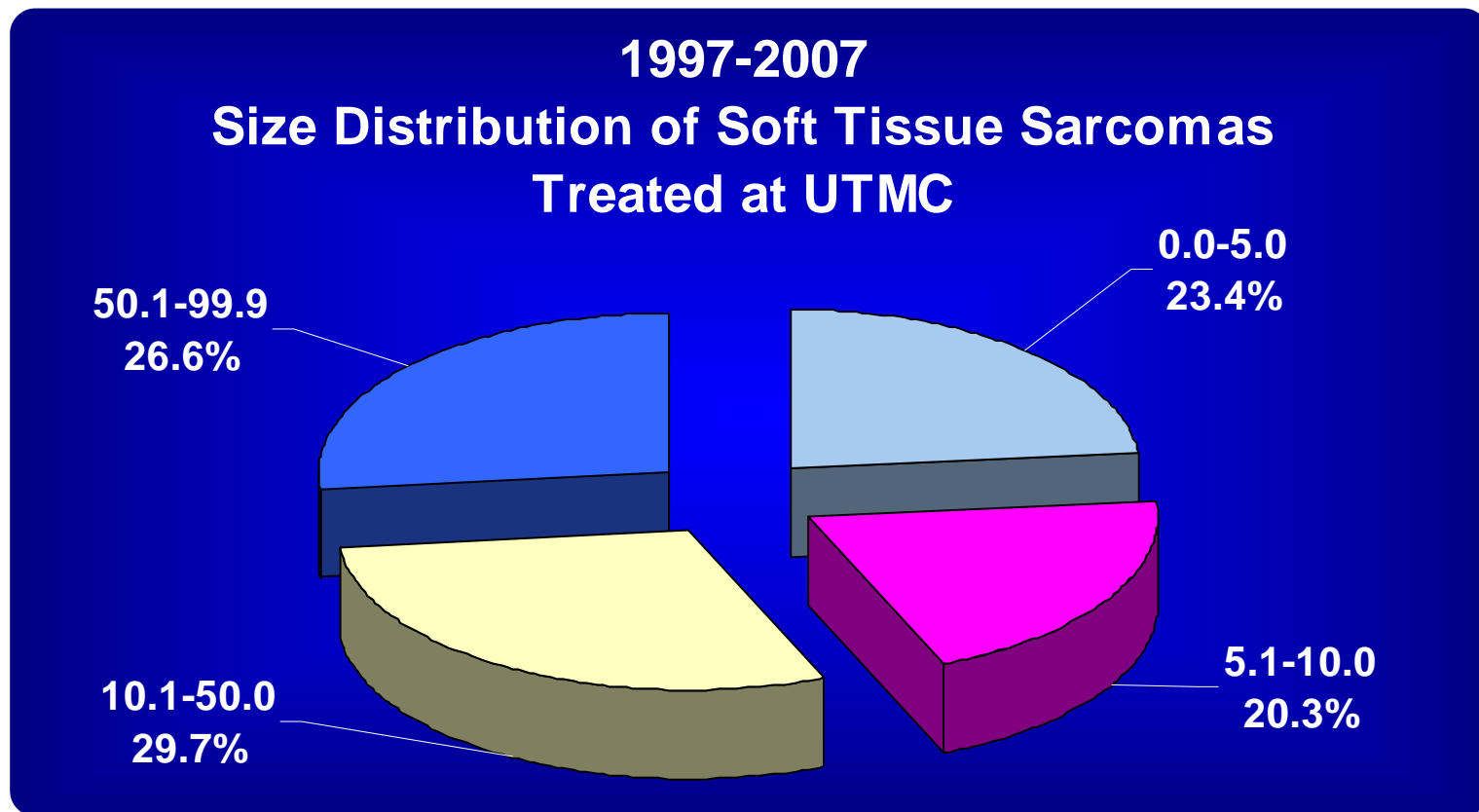


Figure 10:

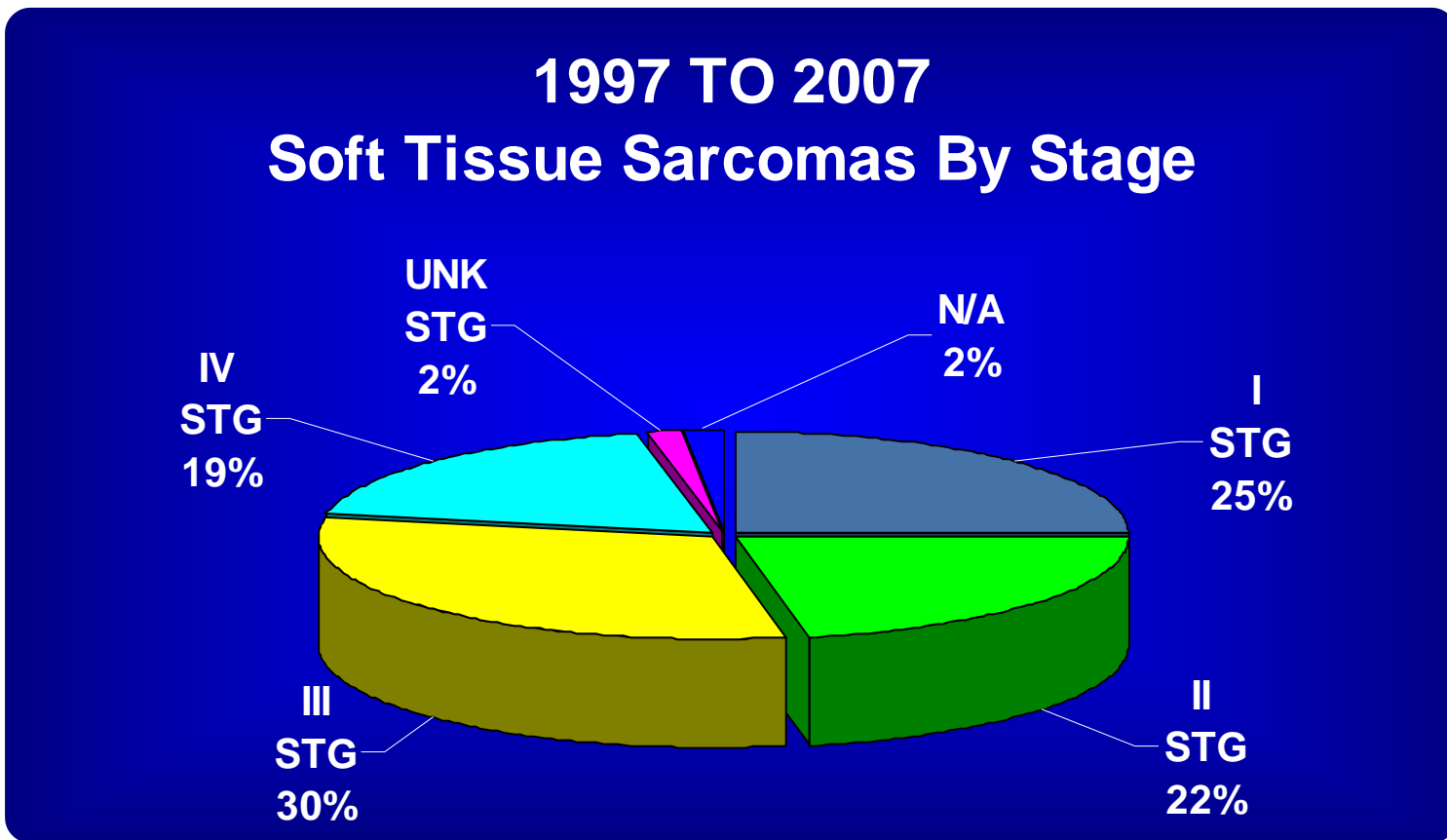


Figure 11:

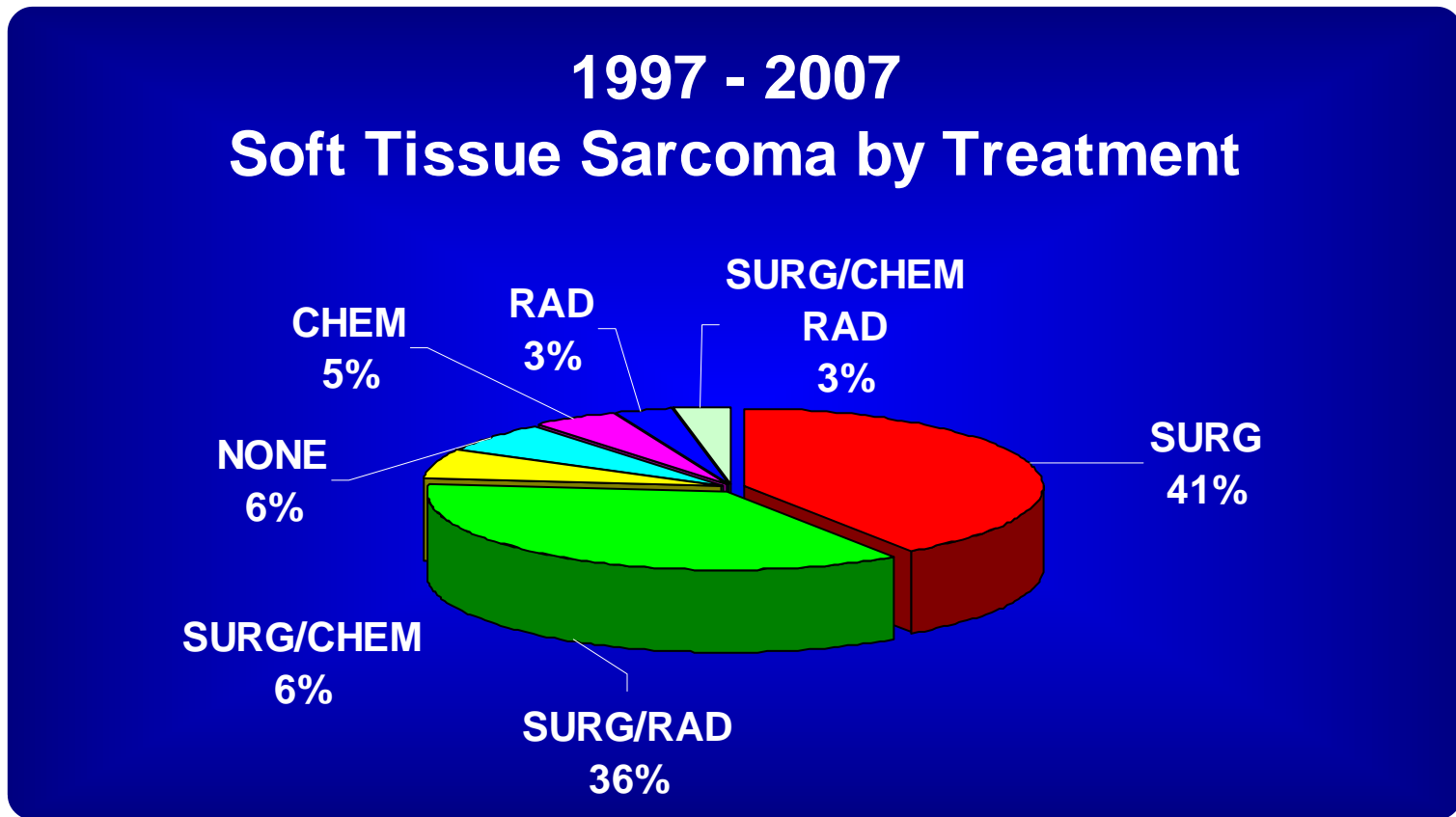
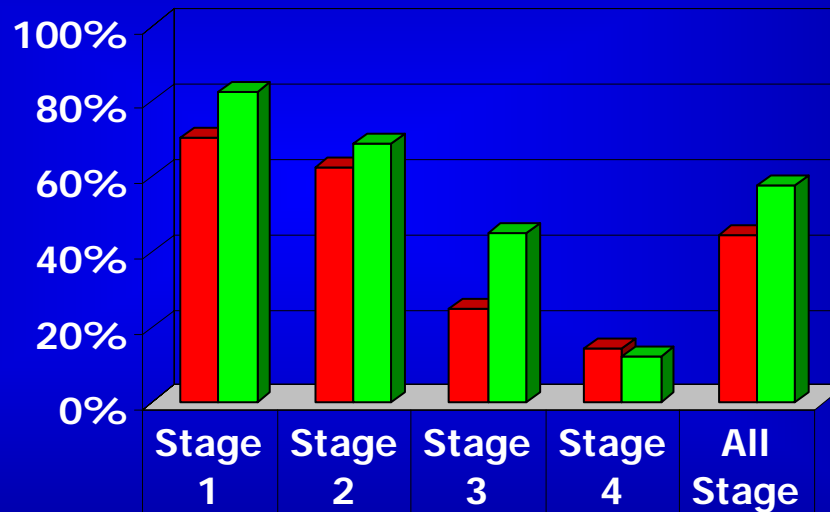


Figure 12:

**UNIVERSITY OF TENNESSEE CANCER INSTITUTE
SOFT TISSUE SARCOMA SURVIVAL 1997 - 2003
COMPARED TO NATIONAL AJCC TNM ED 5**
Source: 2010 National Cancer Database/Commission on Cancer



■ University of TN	70.1%	62.5%	25.0%	14.2%	44.3%
■ National	82.2%	68.7%	44.8%	12.1%	57.5%