

# Stroke

American Stroke  
Association<sup>SM</sup>

A Division of American  
Heart Association



JOURNAL OF THE AMERICAN HEART ASSOCIATION

## **Duplex Ultrasound and Magnetic Resonance Angiography Compared With Digital Subtraction Angiography in Carotid Artery Stenosis: A Systematic Review**

Paul J. Nederkoorn, Yolanda van der Graaf and M.G. Myriam Hunink

*Stroke* 2003;34;1324-1331; originally published online Apr 10, 2003;

DOI: 10.1161/01.STR.0000068367.08991.A2

Stroke is published by the American Heart Association, 7272 Greenville Avenue, Dallas, TX 75214  
Copyright © 2003 American Heart Association. All rights reserved. Print ISSN: 0039-2499. Online  
ISSN: 1524-4628

The online version of this article, along with updated information and services, is  
located on the World Wide Web at:

<http://stroke.ahajournals.org/cgi/content/full/34/5/1324>

Subscriptions: Information about subscribing to Stroke is online at  
<http://stroke.ahajournals.org/subscriptions/>

Permissions: Permissions & Rights Desk, Lippincott Williams & Wilkins, a division of Wolters  
Kluwer Health, 351 West Camden Street, Baltimore, MD 21202-2436. Phone: 410-528-4050. Fax:  
410-528-8550. E-mail:  
[journalpermissions@lww.com](mailto:journalpermissions@lww.com)

Reprints: Information about reprints can be found online at  
<http://www.lww.com/reprints>

# Duplex Ultrasound and Magnetic Resonance Angiography Compared With Digital Subtraction Angiography in Carotid Artery Stenosis

## A Systematic Review

Paul J. Nederkoorn, MD, PhD; Yolanda van der Graaf, MD, PhD; M.G. Myriam Hunink, MD, PhD

**Background and Purpose**—The purpose of this work was to review and compare published data on the diagnostic value of duplex ultrasonography (DUS), MR angiography (MRA), and conventional digital subtraction angiography (DSA) for the diagnosis of carotid artery stenosis.

**Methods**—We performed a systematic review of published studies retrieved through PUBMED, from bibliographies of review papers, and from experts. The English-language medical literature was searched for studies that met the selection criteria: (1) The study was published between 1994 and 2001; (2) MRA and/or DUS was performed to estimate the severity of carotid artery stenosis; (3) DSA was used as the standard of reference; and (4) the absolute numbers of true positives, false negatives, true negatives, and false positives were available or derivable for at least one definition of disease (degree of stenosis).

**Results**—Sixty-three publications on duplex, MRA, or both were included in the analysis, yielding the test results of 64 different patient series on DUS and 21 on MRA. For the diagnosis of 70% to 99% versus <70% stenosis, MRA had a pooled sensitivity of 95% (95% CI, 92 to 97) and a pooled specificity of 90% (95% CI, 86 to 93). These numbers were 86% (95% CI, 84 to 89) and 87% (95% CI, 84 to 90) for DUS, respectively. For recognizing occlusion, MRA yielded a sensitivity of 98% (95% CI, 94 to 100) and a specificity of 100% (95% CI, 99 to 100), and DUS had a sensitivity of 96% (95% CI, 94 to 98) and a specificity of 100% (95% CI, 99 to 100). A multivariable summary receiver-operating characteristic curve (ROC) analysis for diagnosing 70% to 99% stenosis demonstrated that the type of MR scanner predicted the performance of MRA, whereas the presence of verification bias predicted the performance of DUS. For diagnosing occlusion, no significant heterogeneity was found for MRA; for DUS, the presence of verification bias and type of DUS scanner were explanatory variables. MRA had a significantly better discriminatory power than DUS in diagnosing 70% to 99% stenosis (regression coefficient, 1.6; 95% CI, 0.37 to 2.77). No significant difference was found in detecting occlusion (regression coefficient, 0.73; 95% CI, -2.06 to 3.51).

**Conclusions**—These results suggest that MRA has a better discriminatory power compared with DUS in diagnosing 70% to 99% stenosis and is a sensitive and specific test compared with DSA in the evaluation of carotid artery stenosis. For detecting occlusion, both DUS and MRA are very accurate. (*Stroke*. 2003;34:1324-1332.)

**Key Words:** carotid stenosis ■ magnetic resonance angiography ■ meta-analysis ■ ultrasonography, Doppler, duplex

Two large, randomized, clinical trials, The North American Symptomatic Carotid Endarterectomy Trial (NASCET) and the European Carotid Surgery Trial (ECST), have proved the benefit of carotid endarterectomy in patients with severe (70% to 90%) symptomatic carotid artery stenosis.<sup>1,2</sup> Recent publications have shown that subgroups of patients with 50% to 69% stenosis may also expect a small benefit from carotid endarterectomy.<sup>3</sup> The diagnosis of severe stenosis (70% to 99%), however, remains crucial for most patients. The degree of stenosis in the endarterectomy trials was established by digital subtraction angiography (DSA),

### See Editorial Comment, page 1331

which has become the standard of reference for selecting patients for carotid surgery. DSA, however, has a relatively high risk of morbidity and mortality, ranging from 1% to 4% in patients with atherosclerosis.<sup>4</sup> Even patients without apparent neurological complications after DSA have been shown to develop minor asymptomatic infarctions resulting from microembolisms.<sup>5</sup>

MR angiography (MRA) and contrast-enhanced MRA (CE-MRA) are increasingly used supplementary to duplex

Received July 7, 2002; final revision received November 3, 2002; accepted November 27, 2002.

From the Julius Center for Health Sciences and Primary Care, University Medical Center Utrecht, Utrecht, the Netherlands (P.J.N., Y.v.d.G.), and Program for the Assessment of Radiologic Technology, Department of Epidemiology and Biostatistics and Department of Radiology, Erasmus Medical Center, Rotterdam, the Netherlands, and Department of Health Policy and Management, Harvard School of Public Health, Boston, Mass (M.G.M.H.).

Correspondence to M.G.M. Hunink, MD, PhD, Erasmus Medical Center Rotterdam, Room EE 2140, PO Box 1738, 3000 DR Rotterdam, Netherlands. E-mail Hunink@epib.fgg.eur.nl

© 2003 American Heart Association, Inc.

Stroke is available at <http://www.strokeaha.org>

DOI: 10.1161/01.STR.0000068367.08991.A2

ultrasonography (DUS) and conventional DSA in the diagnosis of carotid artery stenosis.<sup>6</sup> Many institutions have published diagnostic studies in which MRA and/or DUS was compared with DSA. The results suggest that the decision to perform carotid endarterectomy could be based on one or a combination of these noninvasive tests. Two meta-analytic reviews have been published that summarize the literature on the diagnostic performance of DUS and MRA from before 1996, one reporting an increasing role for noninvasive testing in carotid artery disease (DUS and MRA),<sup>7</sup> and the other concluding moderate test results for MRA.<sup>8</sup> Recently, a review of previous studies on this topic published between 1993 and 1998 criticized the design of the studies and proposed guidelines for diagnostic studies.<sup>9</sup>

Accordingly, a recent review summarizing publications from 1990 to 1999 concluded that MRA seemed an accurate test in selecting patients for carotid surgery but that evidence was not yet very robust because of the heterogeneity of the studies included.<sup>10</sup> In the mentioned literature, however, variables explaining the observed heterogeneity have not been investigated.

The purpose of this study was to systematically review the contemporary literature and to compare the diagnostic performance of DUS, MRA, and CE-MRA. Our aim was to increase precision by combining published studies and to determine variables that might explain part of the difference in outcome across studies. Recently published guidelines for meta-analyses of randomized, controlled trials were followed when applicable to a meta-analysis on diagnostic tests.<sup>11</sup>

## Methods

### Study Selection

We performed a literature search for publications on the diagnostic performance of DUS, MRA, or a combination of these 2 modalities in patients with carotid artery stenosis in whom DSA was used as the standard of reference. We chose to limit our search to the period from January 1994 to December 2001. Since 1994, there has been a rise in publications on MRA. We decided not to go further back in time because technical possibilities and imaging protocols of these noninvasive tests have developed considerably over time, making comparison between new and old studies less meaningful.

To find the studies, we performed a PUBMED search using the following keywords and all possible related terms: carotid artery and angiography combined with magnetic resonance and/or duplex or ultrasound. We limited the search to publications published in the English language. Reference lists of original and review publications on this subject were checked, and experts on the subject were consulted to find additional studies.

Studies that met the following criteria were included: (1) The study was published between 1994 and 2001; (2) MRA or CE-MRA and/or DUS was performed to estimate the severity of carotid artery stenosis; (3) DSA was used as the reference standard; and (4) the absolute numbers of true positive, false negatives, true negatives, and false positives were available or derivable from the presented data for at least one cutoff criterion for the degree of stenosis based on DSA. We reconstructed these numbers if sensitivity, specificity, and prevalence of disease were presented.

Our intent was to collect the absolute numbers for each study as completely as possible for the following categories of carotid artery stenosis: 0% to 29%, 30% to 49%, 50% to 69%, 70% to 99%, and 100%. Authors were contacted for 2 reasons: (1) to give them the opportunity to send us additional data so that we could work with a complete data set for all described categories, and (2) if neither absolute numbers or sensitivity/specificity was derivable but the

study suggested availability of this data. Studies with occlusion as their main outcome (often describing diagnostic tests only to determine if occlusion was present or not) were excluded if the authors did not respond to our request for more precise specification of the nonocclusion group. We excluded these studies because the main subject of our meta-analysis was treatment decisions based on the category of 70% to 99% stenosis and because the cutoff criteria used in these publications were too diverse to include in the meta-analysis. We also excluded studies with a population of <15 patients. If publications used the same or an overlapping population, we chose the publication from which we could derive the required data in the most straightforward manner. We contacted the authors if it was not clear whether separate published populations were overlapping.

### Data Extraction

Two authors (Y.v.d.G.) and (P.N.) independently extracted data from all publications. All abstracts collected from PUBMED through the described search criteria were evaluated. The full text was studied to check the inclusion criteria from all studies that could not definitely be excluded on the basis of the abstract. From the included publications, the absolute numbers of true positives, false negatives, true negatives, and false positives of the described test modalities were extracted as completely as possible for all the different categories of stenosis: 0% to 29%, 30% to 49%, 50% to 69%, 70% to 99%, and 100%. Sensitivity and specificity were extracted or calculated from the data, and absolute numbers were derived if the prevalence was reported. Additionally, the following variables were extracted for each study population: mean age and range, percentage of men and women, percentage of symptomatic patients, and type of symptoms (amaurosis fugax, transient ischemic attack, or stroke), as well as whether the tests were studied in a consecutive patient population. The following test characteristics were determined: method of stenosis measurement used on DSA (according to NASCET or ECST criteria or a different method), type of MR and/or DUS machine, time interval between DUS and/or MRA and DSA, number of visualized carotid arteries, and whether a different cutoff was used to define severe stenosis (eg, 60% or 80% instead of 70%). We converted cutoff values determined according to ECST criteria to their corresponding NASCET criteria. In studies presenting DUS results, often >1 velocity parameter (peak systolic velocity, end-diastolic velocity, mean velocity) or a ratio was used to determine the degree of stenosis. We chose the parameter that the authors considered optimal. Single peak systolic velocity (PSV) values referring to a degree of stenosis of 70% were extracted if available. We determined whether the DUS thresholds were defined before the study was performed, or if the optimal thresholds had been analyzed afterward on the basis of the results (yielding a higher diagnostic performance). We also noted whether verification bias was present, which may occur if the decision to perform the reference standard procedure depends on the results of the test under investigation.<sup>12</sup> (In practice, DUS is often used as the screening test to select patients for DSA.) In the MRA studies, use of a contrast-enhanced protocol versus time-of-flight (TOF) technique was noted. Finally, we determined whether tests were read with the observer blinded to the results of the other test(s).

Discrepancies between the 2 observers in the extracted data were discussed and, in all cases, resolved through consensus.

### Analyses

The analyses presented are limited to 2 groups: 70% to 99% (severe stenosis) versus <70% and 100% (occlusion) versus <100%. The data collected from the other subgroups under the 70% threshold (0% to 29%, 30% to 49%, 50% to 69%) were not included in the presented analyses. The data in these groups contained too many missing values for a meaningful analysis, even though some publications presented a very complete description of the data and some of the authors gave enthusiastic replies to our request for additional data. Furthermore, we thought that the data of the 30% to 49% and 50% to 69% stenosis categories might suffer from selection and/or verification bias because many institutions use a threshold close to

**TABLE 1. Variables Extracted From Publications and Analyzed in the Described Models for Each Study Population**

1. Test specific positivity criterion (S)*
2. Publication year (with 1994 as reference year)
3. Proportion of carotid arteries studied that were symptomatic (assuming all symptomatic if not mentioned)
4. Consecutive patients included in the cohort? (Yes vs no or not mentioned)
5. Verification bias present? (Yes or cannot be excluded vs no)
6. Blinded interpretation of test results? (Yes vs no mention of blinding or not blinded)
7. Measurement of stenosis by NASCET method? (NASCET scoring system or NASCET equivalent vs NASCET not used or scoring system not mentioned)
8. Choice of a cutoff to define severe stenosis other than the conventional 70%–99% (yes/no)
9. Type of DUS machine used (ATL, Acuson, or Diasonics)
10. CE-MRA technique vs 2- or 3-dimensional TOF-MRA
11. Type of MR machine used (General Electric vs others)
12. Time between noninvasive test and angiography (in days)
13. PSV cutoff value for 70% stenosis on DUS (in cm/s)
14. PSV positivity criterion determined after the study
15. Age

\*The positivity criterion of each study was approximated by calculating  $S = \ln[(TP \times FP)/(TN \times FN)]$ .

†Most studies reporting on non-CE-MRA used a combination of 2- and 3-dimensional TOF.

50% stenosis on DUS as their inclusion criterion to perform DSA. For both reasons, the analyses in these stenosis groups gave very inconsistent preliminary results.

All analyzed variables are listed in Table 1. Sex and distribution of disease (ie, localization of the event) were often missing, which precluded meaningful analysis.

All probability values are approximate. The software package used was Intercooled Stata version 6.0 for Windows.

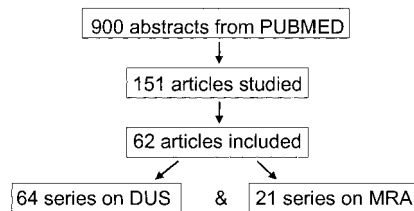
### Pooled Weighted Analysis

We calculated the pooled weighted results of sensitivity, specificity, and diagnostic performance. The diagnostic performance was defined as the natural logarithm of the diagnostic odds ratio:  $D = \ln[(TP \times TN)/(FP \times FN)]$ . Weighting was done with the inverse of the variance. We used a random-effects model to account for the heterogeneity across studies.

### Summary Receiver-Operating Characteristic Curve Analysis

To adjust for the heterogeneity in positivity criteria, a summary receiver-operating characteristic (ROC) curve analysis was performed for each test.<sup>13</sup> Summary ROC analysis is a meta-analytic method to summarize true- and false-positive rates from different diagnostic studies.<sup>14</sup> In this method, the positivity criterion of each study is approximated by calculating  $S = \ln[(TP \times FP)/(TN \times FN)]$ .

Initially, we applied both a fixed- and a random-effects model in all analyses. The fixed-effects model assumes that the operating points from the individual studies lie on one underlying true ROC curve and that the differences in test results can be explained by differences in positivity criteria and other definable covariates. The random-effects summary ROC model assumes that there is always some residual cross-study heterogeneity even after adjustment for differences in positivity criteria and study characteristics such as population size, age, sex, definition of disease, scanner type, MRA technique used, PSV cutoff criterion, blinded scoring, and verification bias.<sup>15</sup> In the remaining sections of this article, we present only

**Figure 1.** Flow diagram of inclusion of patient series.

the methods and results of the random-effects summary ROC model. In the Discussion, we elaborate on the differences in outcome between the random- and fixed-effects models.

### Summary ROC Analysis by Diagnostic Test

Summary ROC models were developed for each diagnostic test separately. In a bivariable analysis, we evaluated each covariate (Table 1) to determine its explanatory value in explaining differences across studies in diagnostic performance (D) after adjustment for the positivity criterion used (S). Variables were considered explanatory in the random-effects analysis if their inclusion decreased the estimate of the between-study variance by at least 10% (which was calculated with  $\tau^2$ , the method of moments), if they had a regression coefficient of at least 1.0 for dummy variables or 1.0 over the range of the variable, or if they were statistically significant ( $P < 0.05$ ).<sup>16</sup>

Subsequently, multivariable summary ROC models were developed for each diagnostic test separately. The explanatory variables from the bivariable analysis were evaluated in a stepwise forward-selection regression model including variables one by one, starting with the variable that decreased  $\tau^2$  the most, and keeping the variable in the model using the same selection criteria as above.  $\tau^2$ , ie, the residual between-study variance calculated with the method of moments, was used as a measure of model fit. A lower  $\tau^2$  value indicates less residual between-study variance and therefore a better model fit and a better explanatory power by the model of the heterogeneity across studies. S (indicating the positivity criterion) was retained in the model regardless of its significance.

### Summary ROC Analysis Comparing MRA and DUS

Finally, we performed a summary ROC analysis for the comparison between DUS and MRA. The significant variables from the multivariable analysis performed for each test separately were included as test-specific covariates in the multivariable comparative model. A dummy variable was added to compare the 2 tests. The regression coefficient of this dummy variable represents the difference in diagnostic performance (D) of MRA compared with DUS. A positive regression coefficient indicates better discriminatory power of MRA compared with DUS; a negative coefficient indicates reduced discriminatory ability of MRA.

To assess whether any individual study was particularly influential on the final results, we performed a jackknife type of sensitivity analysis of the final comparative model in which the analysis was repeated multiple times, each time excluding one study.

## Results

### Overview of Studies

The PUBMED search yielded a little more than 900 references. After evaluating the abstracts, we retrieved 151 publications for further study. Sixty-two articles met our inclusion criteria completely.<sup>17–78</sup> The included 62 publications yielded 85 separate study populations: 21 series on MRA and 64 series on DUS (Figure 1). Nine publications reported on both MRA and DUS results.<sup>17,24,37,63,66,71,73–75</sup> Five publications presented >1 study population and/or multicenter studies containing data varying from 2 to 10 institutions.<sup>24,25,47,59,61</sup> Forty-six authors were contacted to obtain

**TABLE 2. Pooled Weighted Sensitivity and Specificity Calculated in a Random-Effects Model**

	Pooled Sensitivity, % (95% CI)		Pooled Specificity, % (95% CI)	
	MRA	DUS	MRA	DUS
70%–99% vs <70%	95 (92–97)	86 (84–89)	90 (86–93)	87 (84–90)
<100% vs 100%	98 (94–100)	96 (94–98)	100 (99–100)	100 (99–100)

additional data. Three of these authors were contacted because different publications suggested the availability of data on (part of) the same study population. The overall response rate was 30%. Thirteen authors replied and sent us their more complete data. Two authors did answer but wrote that they could not retrieve the necessary numbers. Of the remaining 31 publications, 20 were nevertheless included on the basis of the reported results only. Although several reports are now available on gadolinium-enhanced MRA, test results validated with DSA as the reference standard in a population >15 patients were published in only 4 series.<sup>21,24,40,42</sup>

### Pooled Weighted Analysis

For the diagnosis of 70% to 99% versus <70% stenosis, MRA had a pooled sensitivity of 95% (95% CI, 92 to 97) and a pooled specificity of 90% (95% CI, 86 to 93) (Table 2). These numbers were 86% (95% CI, 84 to 89) and 87% (95% CI, 84 to 90) for DUS, respectively. For diagnosing occlusion (<100% versus 100%), MRA had a sensitivity of 98% (95% CI, 94 to 100) and a specificity of 100% (95% CI, 99 to 100); for DUS, these numbers were 96% (95% CI, 94 to 98) and 100% (95% CI, 99 to 100). These pooled data indicate a better discriminatory power for MRA in diagnosing severe stenosis (70% to 99%), whereas MRA and DUS are equally good in recognizing carotid occlusion (100%). The pooled values of D (the natural logarithm of the diagnostic odds ratio) were very similar between tests: 4.1 (95% CI, 3.5 to 4.8) for MRA versus 4.0 (95% CI, 3.5 to 4.5) for DUS in the 70% to 99% category and 6.5 (95% CI, 5.7 to 7.4) for MRA versus 6.5 (95% CI, 5.9 to 7.0) for DUS in diagnosing occlusion.

### Summary ROC Analysis by Diagnostic Test

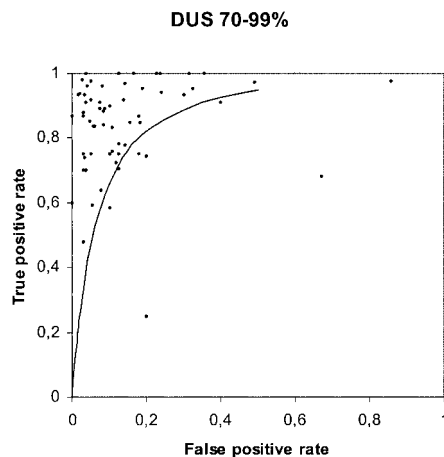
In the multivariable model for the diagnosis of 70% to 99% stenosis, type of MR scanner was a significant predictor for the diagnostic performance of MRA. Of note, the regression coefficient for CE-MRA versus non-CE-MRA techniques (practically always a combination of 2- and 3-dimensional TOF) was close to 0 and nonsignificant (−0.35; 95% CI, −1.80 to 1.10). The presence of verification bias and choice of a different cutoff to define severe stenosis were associated with better DUS performance. In recognizing occlusion, no significant heterogeneity was demonstrated among the MRA studies. Presence of verification bias and type of DUS scanner were significant predictors for DUS.

### Summary ROC Analysis Comparing MRA and DUS

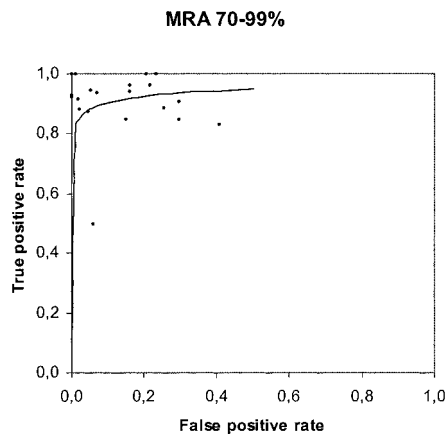
The multivariable comparative model with adjustment for significant predictors demonstrated a regression coefficient

for MRA versus DUS of 1.6 (95% CI, 0.37 to 2.77;  $P=0.01$ ) for 70% to 99% versus <70% stenosis, indicating that MRA discriminates significantly better than DUS. The jackknife sensitivity analyses, in which each study was excluded one by one from the final model, did not demonstrate any disproportionate influences of individual studies (regression coefficient for MRA versus DUS varied from 1.25 to 1.87 and was always significant). The  $\tau^2$  value for the final comparative model for severe stenosis was 1.29, indicating a moderate model fit and some residual between-study variance. The multivariable summary ROC curves for severe stenosis presented in Figures 2 and 3 were based on the final comparative model. The summary ROC curve for DUS was adjusted to reflect a cutoff of 70% for severe stenosis and the absence of verification bias (Figure 2). The summary ROC curve for MRA was adjusted to reflect the most commonly used types of MR scanners (Figure 3). The dots represent the original true-positive and true-negative rates of the individual publications.

In differentiating occlusion from <100% stenosis, the regression coefficient for MRA versus DUS was 0.73 (95% CI, −2.06 to 3.51;  $P=0.51$ ), indicating no difference in diagnostic performance. The jackknife sensitivity analysis demonstrated that the results were not influenced by any particular study (range regression coefficient, 0.42 to 1.12; never significant). The  $\tau^2$  value for the final model for occlusions was 0, indicating excellent model fit and no residual between-study variance. The summary ROC curves for the diagnosis of occlusion (100%) were both close to perfect (not shown).



**Figure 2.** Multivariable summary ROC model (line) for diagnosing severe stenosis on DUS and original data from individual studies (dots). Summary ROC curve is adjusted to reflect a cutoff of 70% for severe stenosis and the absence of verification bias.



**Figure 3.** Multivariable summary ROC model (line) for diagnosing 70% to 99% versus <70% stenosis on MRA and original data from individual studies (dots). Summary ROC curve is adjusted to reflect the most commonly used types of MR scanners.

### Discussion

In this article, we systematically reviewed and compared the diagnostic value of DUS and MRA with DSA for the diagnosis of carotid artery stenosis. Our results suggest that for the distinction of <70% versus 70% to 99% stenosis, MRA has a significantly better discriminatory power than DUS, whereas for the distinction between occlusion versus no occlusion, there is no significant difference in diagnostic performance. According to our random-effects model, the difference between DUS results across studies for diagnosing 70% to 99% stenosis can be explained in part by the presence of verification bias and choice of a different cutoff to define severe stenosis. For MRA, the type of MR scanner was an explanatory variable. For diagnosing 100% versus <100% with DUS, the presence of verification bias and type of DUS scanner were explanatory variables; for MRA, no heterogeneity was found among the different studies.

An earlier meta-analysis published by Blakeley et al<sup>7</sup> in 1995 concluded that DUS and MRA had similar diagnostic performance in predicting carotid artery occlusion and >70% stenosis. In our study, we found a better discriminatory power for MRA compared with their results. In the study by Blakeley et al, the literature from 1977 to 1993 was reviewed, whereas our literature search started with 1994. Improved MRA technology might explain an increase in diagnostic performance of MRA. Kallmes et al<sup>8</sup> reviewed MRA studies published between 1990 and 1994 and found lower sensitivity for MRA in recognizing severe carotid artery stenosis than we did.<sup>8</sup> Furthermore, they discussed whether the asymptomatic arteries should be excluded from the results. Exclusion of the asymptomatic side in their analyses gave even lower sensitivities. Finally, a recent review by Westwood et al<sup>10</sup> summarizing publications of 1990 to 1999 concluded that MRA seemed test in selecting patients for carotid surgery but that evidence was not yet very robust because of the heterogeneity of the studies included.<sup>10</sup> This study also applied a ROC analysis, and their results on MRA are very similar to ours. Our article differs substantially from the literature in that we performed a systematic review of both MRA and

DUS and compared them. Despite the introduction of MRA for imaging the carotid artery, DUS remains very important in the initial workup of patients suspected of carotid artery stenosis. Furthermore, our article differs in that we present variables that explain the heterogeneity observed in literature.<sup>9,10</sup>

A limitation in the collection of our data was the fact that, to be able to perform a summary ROC analysis, we could include only those studies from which absolute numbers (true positives, false positives, true negatives, false negatives) for at least one defined threshold were available or derivable. Often, only sensitivities and specificities were presented. When we were unable to reconstruct the absolute numbers or when authors did not reply to our request for additional data, we had to exclude the study. Therefore, it was possible to include only a selection of the contemporary literature in this analysis. Furthermore, in the included papers, we often found incomplete or missing data concerning population baseline characteristics, distribution of disease, and technical aspects of the imaging protocols. For some of the variables, these omissions precluded meaningful analysis.

Another limitation of our study is that we used angiography as the reference standard test. Angiography has several limitations related to the fact that it consists of a limited number of projections of the vessel lumen. The true lumen can be more severely stenosed, and information regarding the extent of plaque and plaque morphology is more readily available from ultrasonography and MR imaging.<sup>79,80</sup> The vast majority of studies evaluating DUS and MRA, however, used angiography as the reference, and in reviewing these studies, we were therefore compelled to do so also.

In the meta-analysis, we first calculated the pooled sensitivities and specificities. This method provides a relatively crude estimate of the overall diagnostic performance of the different tests. The pooled weighted analysis showed that both DUS and MRA are highly sensitive and specific for diagnosing carotid artery occlusion. For the diagnosis of occlusion, only the absence of signal needs to be determined, whereas judgment of the severity of a stenosis is not necessary. For detecting the 70% cutoff, MRA showed better sensitivity and slightly better specificity than DUS. MRA probably gives a more precise estimate of the degree of stenosis because it provides a direct measurement of the stenotic lumen (NASCET method), whereas DUS allows only an indirect estimate through measurement of parameters based on blood flow velocities. Therefore, DUS gives a wider dispersion in results compared with DSA, resulting in lower sensitivities and specificities. The pooled sensitivity and specificity of 95% and 90%, respectively, for MRA in detecting severe stenosis are very high, and this technique may improve even further in the near future.

In addition to calculating pooled weighted sensitivities and specificities, we performed a summary ROC analysis, which is especially useful to evaluate overall diagnostic performance. The main advantage of this method is that it adjusts for different positivity criteria, which cannot be achieved with pooling sensitivities and specificities. Initially, we studied both a fixed- and a random-effects model in the summary ROC analyses. Although the random-effects model seems

more elegant in a meta-analysis combining the results from diverse studies, a fixed-effects model can also be justified in a diagnostic meta-analysis. Study populations selected for a specific test and disease often have comparable baseline characteristics, which supports the assumption of a true underlying ROC curve. Because of the stricter assumptions, the fixed-effects model can potentially identify additional explanatory variables. In our study, the fixed- and random-effects models showed good consistency in finding significant variables that explain part of the heterogeneity of the different publications. For DUS, publication year was found as an additional explanatory variable for the diagnosis of severe stenosis (70% to 99%) when the fixed-effects model was applied. Earlier studies showed better diagnostic performance, indicating a possible effect of publication bias. Alternatively, this finding may indicate the selection bias that commonly occurs in early studies of new diagnostic technologies. In the diagnosis of occlusion, a consecutive study population was found to be an additional significant variable for MRA.

Remarkably, the type of MR scanner but not the type of DUS scanner was shown to be an explanatory variable in the diagnosis of a 70% to 99% stenosis. It is generally known that different DUS machines with different technologists in different institutions show variable test results, even if the same thresholds for the test parameters are used.<sup>81</sup> Although we showed a difference across MRA scanners, the results did not indicate a difference in diagnostic performance depending on the imaging technique used. Technically there is a major difference between non-CE-MRA and CE-MRA. In practically all studies reporting on non-CE-MRA, a combination of 2- and 3-dimensional TOF was used. We evaluated the effect of MRA technique in the summary ROC analysis and found the regression coefficient for CE-MRA versus TOF to be close to 0 and nonsignificant. Thus, according to the results published so far, the technical difference between CE-MRA and TOF techniques does not seem to translate into a significant difference in diagnostic performance. A caveat is, however, that only 4 of the 21 MRA series were based on CE-MRA.

The fact that verification bias plays an important role in detecting 70% to 99% stenoses on DUS is a plausible and important finding. Verification bias may exist if the decision to perform the reference standard procedure depends on the results of the test under investigation. In the included studies, DUS has often been used as a screening test to decide whether to perform DSA.

In conclusion, our results suggest that MRA has a better discriminatory power compared with DUS in recognizing 70% to 99% stenosis and is a sensitive and specific test compared with DSA in the evaluation of carotid artery stenosis. For detecting occlusion of the carotid artery, both modalities are very accurate. To determine whether noninvasive tests can replace DSA in clinical practice, however, not only the test results but also the associated costs and effectiveness should be taken into account.

### Acknowledgments

This work was funded in part by a grant (OG/30) from the Dutch Ministry of Health, Welfare, and Sports and by a program grant

(NWO/904-66-091) from the Netherlands Organization for Scientific Research.

### References

- Barnett HJ, Taylor DW, Eliasziw M, Fox AJ, Ferguson GG, Haynes RB, Rankin RN, Clagett GP, Hachinski VC, Sackett DL, Thorpe KE, Meldrum HE. Benefit of carotid endarterectomy in patients with symptomatic moderate or severe stenosis: North American Symptomatic Carotid Endarterectomy Trial Collaborators. *N Engl J Med.* 1998;339:1415-1425.
- European carotid Surgery Trialists' Collaborative Group. Randomised trial of endarterectomy for recently symptomatic carotid stenosis: final results of the MRC European Carotid Surgery Trial (ECST). *Lancet.* 1998;351:1379-1387.
- Cina CS, Clase CM, Haynes BR. Refining the indications for carotid endarterectomy in patients with symptomatic carotid stenosis: a systematic review. *J Vasc Surg.* 1999;30:606-617.
- Hankey GJ, Warlow CP, Molyneux AJ. Complications of cerebral angiography for patients with mild carotid territory ischaemia being considered for carotid endarterectomy. *J Neurol Neurosurg Psychiatry.* 1990;53:542-548.
- Bendszus M, Koltzenburg M, Burger R, Warmuth-Metz M, Hofmann E, Solymosi L. Silent embolism in diagnostic cerebral angiography and neurointerventional procedures: a prospective study. *Lancet.* 1999;354:1594-1597.
- Leclerc X, Gauvrit JY, Nicol L, Pruvo JP. Contrast-enhanced MR angiography of the craniocervical vessels: a review. *Neuroradiology.* 1999;41:867-874.
- Blakeley DD, Oddone EZ, Hasselblad V, Simel DL, Matchar DB. Non-invasive carotid artery testing: a meta-analytic review. *Ann Intern Med.* 1995;122:360-367.
- Kallmes DF, Omary RA, Dix JE, Evans AJ, Hillman BJ. Specificity of MR angiography as a confirmatory test of carotid artery stenosis. *AJNR Am J Neuroradiol.* 1996;17:1501-1506.
- Rothwell PM, Pendlebury ST, Wardlaw J, Warlow CP. Critical appraisal of the design and reporting of studies of imaging and measurement of carotid stenosis. *Stroke.* 2000;31:1444-1450.
- Westwood ME, Kelly S, Berry E, Bamford JM, Gough MJ, Airey CM, Meaney JF, Davies LM, Cullingworth J, Smith MA. Use of magnetic resonance angiography to select candidates with recently symptomatic carotid stenosis for surgery: systematic review. *BMJ.* 2002;324:198.
- Moher D, Cook DJ, Eastwood S, Olkin I, Rennie D, Stroup DF. Improving the quality of reports of meta-analyses of randomised controlled trials: the QUOROM statement: Quality of Reporting of Meta-Analyses. *Lancet.* 1999;354:1896-1900.
- Begg CB, Greenes RA. Assessment of diagnostic tests when disease verification is subject to selection bias. *Biometrics.* 1983;39:207-215.
- Irwig L, Tosteson AN, Gatsonis C, Lau J, Colditz G, Chalmers TC, Mosteller F. Guidelines for meta-analyses evaluating diagnostic tests. *Ann Intern Med.* 1994;120:667-676.
- Littenberg B, Moses LE. Estimating diagnostic accuracy from multiple conflicting reports: a new meta-analytic method. *Med Decis Making.* 1993;13:313-321.
- de Vries SO, Hunink MG, Polak JF. Summary receiver operating characteristic curves as a technique for meta-analysis of the diagnostic performance of duplex ultrasonography in peripheral arterial disease. *Acad Radiol.* 1996;3:361-369.
- Thompson SG, Sharp SJ. Explaining heterogeneity in meta-analysis: a comparison of methods. *Stat Med.* 1999;18:2693-2708.
- Binaghi S, Maeder P, Uske A, Meuwly JY, Devuyt G, Meuli RA. Three-dimensional computed tomography angiography and magnetic resonance angiography of carotid bifurcation stenosis. *Eur Neurol.* 2001;46:25-34.
- Koga M, Kimura K, Minematsu K, Yamaguchi T. Diagnosis of internal carotid artery stenosis greater than 70% with power Doppler duplex sonography. *AJNR Am J Neuroradiol.* 2001;22:413-417.
- Neschis DG, Lexa FJ, Davis JT, Carpenter JP. Duplex criteria for determination of 50% or greater carotid stenosis. *J Ultrasound Med.* 2001;20:207-215.
- Qureshi AI, Suri MF, Ali Z, Kim SH, Fessler RD, Ringer AJ, Guterman LR, Budny JL, Hopkins LN. Role of conventional angiography in evaluation of patients with carotid artery stenosis demonstrated by Doppler ultrasound in general practice. *Stroke.* 2001;32:2287-2291.

21. Randoux B, Marro B, Koskas F, Duyme M, Sahel M, Zouaoui A, Marsault C. Carotid artery stenosis: prospective comparison of CT, three-dimensional gadolinium-enhanced MR, and conventional angiography. *Radiology*. 2001;220:179–185.
22. Bluth EI, Sunshine JH, Lyons JB, Beam CA, Troxclair LA, Althans-Kopecky L, Crewson PE, Sullivan MA, Smetherman DH, Heidenreich PA, Neiman HL, Burkhardt JH. Power Doppler imaging: initial evaluation as a screening examination for carotid artery stenosis. *Radiology*. 2000;215:791–800.
23. Huston J III, James EM, Brown RD Jr, Lefsrud RD, Ilstrup DM, Robertson EF, Meyer FB, Hallett JW. Redefined duplex ultrasonographic criteria for diagnosis of carotid artery stenosis. *Mayo Clin Proc*. 2000;75:1133–1140.
24. Serfaty JM, Chirossel P, Chevallier JM, Ecochard R, Froment JC, Douek PC. Accuracy of three-dimensional gadolinium-enhanced MR angiography in the assessment of extracranial carotid artery disease. *AJR Am J Roentgenol*. 2000;175:455–463.
25. Back MR, Wilson JS, Rushing G, Stordahl N, Linden C, Johnson BL, Bandyk DF. Magnetic resonance angiography is an accurate imaging adjunct to duplex ultrasound scan in patient selection for carotid endarterectomy. *J Vasc Surg*. 2000;32:429–438.
26. Ballotta E, Da Giau G, Abbruzzese E, Saladini M, Renon L, Scannapieco G, Meneghetti G. Carotid endarterectomy without angiography: can clinical evaluation and duplex ultrasonographic scanning alone replace traditional arteriography for carotid surgery workup? A prospective study. *Surgery*. 1999;126:20–27.
27. Dippel DW, de Kinkelder A, Bakker SL, van Kooten F, van Overhagen H, Koustaal PJ. The diagnostic value of colour duplex ultrasound for symptomatic carotid stenosis in clinical practice. *Neuroradiology*. 1999;41:1–8.
28. Golledge J, Ellis M, Sabharwal T, Sikdar T, Davies AH, Greenhalgh RM. Selection of patients for carotid endarterectomy. *J Vasc Surg*. 1999;30:122–130.
29. Grant EG, Duerinckx AJ, El Saden S, Melany ML, Hathout G, Zimmerman P, Cohen SN, Singh R, Baker JD. Doppler sonographic parameters for detection of carotid stenosis: is there an optimum method for their selection? *AJR Am J Roentgenol*. 1999;172:1123–1129.
30. Ranke C, Creutzig A, Becker H, Trappe HJ. Standardization of carotid ultrasound: a hemodynamic method to normalize for interindividual and interequipment variability. *Stroke*. 1999;30:402–406.
31. Soulez G, Therasse E, Robillard P, Fontaine A, Denbow N, Bourgouin P, Oliva VL. The value of internal carotid systolic velocity ratio for assessing carotid artery stenosis with Doppler sonography. *AJR Am J Roentgenol*. 1999;172:207–212.
32. AbuRahma AF, Robinson PA, Strickler DL, Alberts S, Young L. Proposed new duplex classification for threshold stenoses used in various symptomatic and asymptomatic carotid endarterectomy trials. *Ann Vasc Surg*. 1998;12:349–358.
33. Bendick PJ, Brown OW, Hernandez D, Glover JL, Bove PG. Three-dimensional vascular imaging using Doppler ultrasound. *Am J Surg*. 1998;176:183–187.
34. Criswell BK, Langsfeld M, Tullis MJ, Marek J. Evaluating institutional variability of duplex scanning in the detection of carotid artery stenosis. *Am J Surg*. 1998;176:591–597.
35. Curley PJ, Norrie L, Nicholson A, Galloway JM, Wilkinson AR. Accuracy of carotid duplex is laboratory specific and must be determined by internal audit. *Eur J Vasc Endovasc Surg*. 1998;15:511–514.
36. Elmore JR, Franklin DP, Thomas DD, Youkey JR. Carotid endarterectomy: the mandate for high quality duplex. *Ann Vasc Surg*. 1998;12:156–162.
37. Jackson MR, Chang AS, Robles HA, Gillespie DL, Olsen SB, Kaiser WJ, Goff JM, O'Donnell SD, Rich NM. Determination of 60% or greater carotid stenosis: a prospective comparison of magnetic resonance angiography and duplex ultrasound with conventional angiography. *Ann Vasc Surg*. 1998;12:236–243.
38. Muller M, Bartylla K, Rolshausen A, Piegras U, Schimrigk K. Influence of the angiographic internal carotid artery stenosis assessment method on indicating carotid surgery. *Vasa*. 1998;27:24–28.
39. Magarelli N, Scarabino T, Simeone AL, Florio F, Carriero A, Salvolini U, Bonomo L. Carotid stenosis: a comparison between MR and spiral CT angiography. *Neuroradiology*. 1998;40:367–373.
40. Remonda L, Heid O, Schroth G. Carotid artery stenosis, occlusion, and pseudo-occlusion: first-pass, gadolinium-enhanced, three-dimensional MR angiography: preliminary study. *Radiology*. 1998;209:95–102.
41. Scarabino T, Carriero A, Magarelli N, Florio F, Giannatempo GM, Bonomo L, Salvolini U. MR angiography in carotid stenosis: a comparison of three techniques. *Eur J Radiol*. 1998;28:117–125.
42. Slosman F, Stolpen AH, Lexa FJ, Schnall MD, Langlotz CP, Carpenter JP, Goldberg HI. Extracranial atherosclerotic carotid artery disease: evaluation of non-breath-hold three-dimensional gadolinium-enhanced MR angiography. *AJR Am J Roentgenol*. 1998;170:489–495.
43. Alexandrov AV, Brodie DS, McLean A, Hamilton P, Murphy J, Burns PN. Correlation of peak systolic velocity and angiographic measurement of carotid stenosis revisited. *Stroke*. 1997;28:339–342.
44. Chen JC, Salvian AJ, Taylor DC, Teal PA, Marotta TR, Hsiang YN. Can duplex ultrasonography select appropriate patients for carotid endarterectomy? *Eur J Vasc Endovasc Surg*. 1997;14:451–456.
45. Link J, Brossmann J, Penselin V, Gluer CC, Heller M. Common carotid artery bifurcation: preliminary results of CT angiography and color-coded duplex sonography compared with digital subtraction angiography. *AJR Am J Roentgenol*. 1997;168:361–365.
46. Padayachee TS, Cox TC, Modaresi KB, Colchester AC, Taylor PR. The measurement of internal carotid artery stenosis: comparison of duplex with digital subtraction angiography. *Eur J Vasc Endovasc Surg*. 1997;13:180–185.
47. Schwartz SW, Chambless LE, Baker WH, Broderick JP, Howard G. Consistency of Doppler parameters in predicting arteriographically confirmed carotid stenosis: Asymptomatic Carotid Atherosclerosis Study Investigators. *Stroke*. 1997;28:343–347.
48. Steinke W, Ries S, Artemis N, Schwartz A, Hennerici M. Power Doppler imaging of carotid artery stenosis: comparison with color Doppler flow imaging and angiography. *Stroke*. 1997;28:1981–1987.
49. Worthy SA, Henderson J, Griffiths PD, Oates CP, Gholkar A. The role of duplex sonography and angiography in the investigation of carotid artery disease. *Neuroradiology*. 1997;39:122–126.
50. Busuttill SJ, Franklin DP, Youkey JR, Elmore JR. Carotid duplex overestimation of stenosis due to severe contralateral disease. *Am J Surg*. 1996;172:144–147.
51. Golledge J, Wright R, Pugh N, Lane IF. Colour-coded duplex assessment alone before carotid endarterectomy. *Br J Surg*. 1996;83:1234–1237.
52. Griewing B, Doherty C, Kessler C. Power Doppler ultrasound examination of the intracerebral and extracerebral vasculature. *J Neuroimaging*. 1996;6:32–35.
53. Hansen F, Bergqvist D, Lindblad B, Lindh M, Matzsch T, Lanne T. Accuracy of duplex sonography before carotid endarterectomy: a comparison with angiography. *Eur J Vasc Endovasc Surg*. 1996;12:331–336.
54. Hood DB, Mattos MA, Mansour A, Ramsey DE, Hodgson KJ, Barkmeier LD, Sumner DS. Prospective evaluation of new duplex criteria to identify 70% internal carotid artery stenosis. *J Vasc Surg*. 1996;23:254–261.
55. Kagawa R, Moritake K, Shima T, Okada Y. Validity of B-mode ultrasonographic findings in patients undergoing carotid endarterectomy in comparison with angiographic and clinicopathologic features. *Stroke*. 1996;27:700–705.
56. Paivansalo M, Leinonen S, Turunen J, Tikkakoski T, Suramo I. Quantification of carotid artery stenosis with various Doppler velocity parameters. *Rofo*. 1996;164:108–113.
57. Bray JM, Galland F, Lhoste P, Nicolau S, Dubas F, Emile J, Pillet J. Colour Doppler and duplex sonography and angiography of the carotid artery bifurcations: prospective, double-blind study. *Neuroradiology*. 1995;37:219–224.
58. Browman MW, Cooperberg PL, Harrison PB, Marsh JI, Mallek N. Duplex ultrasonography criteria for internal carotid stenosis of more than 70% diameter: angiographic correlation and receiver operating characteristic curve analysis. *Can Assoc Radiol J*. 1995;46:291–295.
59. Chang YJ, Golby AJ, Albers GW. Detection of carotid stenosis: from NASCET results to clinical practice. *Stroke*. 1995;26:1325–1328.
60. Derdeyn CP, Powers WJ, Moran CJ, Cross DT III, Allen BT. Role of Doppler US in screening for carotid atherosclerotic disease. *Radiology*. 1995;197:635–643.
61. Eliasziw M, Rankin RN, Fox AJ, Haynes RB, Barnett HJ. Accuracy and prognostic consequences of ultrasonography in identifying severe carotid artery stenosis: North American Symptomatic Carotid Endarterectomy Trial (NASCET) Group. *Stroke*. 1995;26:1747–1752.
62. Fiori L, Parenti G. The role of pulse-wave Doppler sonography in quantifying internal carotid stenosis. *Eur Neurol*. 1995;35:354–358.
63. Kent KC, Kuntz KM, Patel MR, Kim D, Klufas RA, Whittemore AD, Polak JF, Skillman JJ, Edelman RR. Perioperative imaging strategies for carotid endarterectomy: an analysis of morbidity and cost-effectiveness in symptomatic patients. *JAMA*. 1995;20:274:888–893.

64. Mansour MA, Mattos MA, Hood DB, Hodgson KJ, Barkmeier LD, Ramsey DE, Sumner DS. Detection of total occlusion, string sign, and preocclusive stenosis of the internal carotid artery by color-flow duplex scanning. *Am J Surg*. 1995;170:154–158.
65. Moneta GL, Edwards JM, Papanicolaou G, Hatsukami T, Taylor-LM J, Strandness DEJ, et al. Screening for asymptomatic internal carotid artery stenosis: duplex criteria for discriminating 60% to 99% stenosis. *J Vasc Surg*. 1995;21:989–994.
66. Nicholas GG, Osborne MA, Jaffe JW, Reed JF III. Carotid artery stenosis: preoperative noninvasive evaluation in a community hospital. *J Vasc Surg*. 1995;22:9–16.
67. Rodrigus IE, De Maeseneer MG, Van Schil PE, Pickut BA, d'Archambeau OC, Vanmaele RG. Colour duplex scanning versus angiography: a retrospective assessment of carotid stenosis. *Cardiovasc Surg*. 1995;3:213–216.
68. Dadachanji MC, Shroff MM, Modi D, Jankharia BG. Comparison of MR angiography with contrast angiography for the diagnosis of carotid artery stenosis. *J Assoc Physicians India*. 1995;43:92–95.
69. Ballard JL, Fleig K, De Lange M, Killeen JD. The diagnostic accuracy of duplex ultrasonography for evaluating carotid bifurcation. *Am J Surg*. 1994;168:123–126.
70. Branas CC, Weingarten MS, Czeredarczuk M, Schafer PF. Examination of carotid arteries with quantitative color Doppler flow imaging. *J Ultrasound Med*. 1994;13:121–127.
71. Currie IC, Murphy KP, Jones AJ, Cole SE, Wakeley CJ, Wilson YG, Baird RN, Lamont PM. Magnetic resonance angiography or IADSA for diagnosis of carotid pseudo occlusion? *Eur J Vasc Surg*. 1994;8:562–566.
72. Mattos MA, Hodgson KJ, Faught WE, Mansour A, Barkmeier LD, Ramsey DE, Sumner DS. Carotid endarterectomy without angiography: is color-flow duplex scanning sufficient? *Surgery*. 1994;116:776–782.
73. Mittl RL, Jr, Broderick M, Carpenter JP, Goldberg HI, Listerud J, Mishkin MM, Berkowitz HD, Atlas SW. Blinded-reader comparison of magnetic resonance angiography and duplex ultrasonography for carotid artery bifurcation stenosis. *Stroke*. 1994;25:4–10.
74. White JE, Russell WL, Greer MS, Whittle MT. Efficacy of screening MR angiography and Doppler ultrasonography in the evaluation of carotid artery stenosis. *Am Surg*. 1994;60:340–348.
75. Young GR, Humphrey PR, Shaw MD, Nixon TE, Smith ET. Comparison of magnetic resonance angiography, duplex ultrasound, and digital subtraction angiography in assessment of extracranial internal carotid artery stenosis. *J Neurol Neurosurg Psychiatry*. 1994;57:1466–1478.
76. Anderson CM, Lee RE, Levin DL, de la Torre AS, Saloner D. Measurement of internal carotid artery stenosis from source MR angiograms. *Radiology*. 1994;193:219–226.
77. De Marco JK, Nesbit GM, Wesbey GE, Richardson D. Prospective evaluation of extracranial carotid stenosis: MR angiography with maximum-intensity projections and multiplanar reformation compared with conventional angiography. *AJR Am J Roentgenol*. 1994;163:1205–1212.
78. Nokes SR, Harter SB. Radiological case of the month: diagnosis of carotid artery stenosis: comparison of MR angiography with contrast angiography. *J Ark Med Soc*. 1994;90:599–602.
79. Pan XM, Saloner D, Reilly LM, Bowersox JC, Murray SP, Anderson CM, Gooding GA, Rapp JH. Assessment of carotid artery stenosis by ultrasonography, conventional angiography, and magnetic resonance angiography: correlation with ex vivo measurement of plaque stenosis. *J Vasc Surg*. 1995;21:82–89; discussion 88–89.
80. Elgersma OE, Wust AF, Buijs PC, van Der Graaf Y, Eikelboom BC, Mali WP. Multidirectional depiction of internal carotid arterial stenosis: three-dimensional time-of-flight MR angiography versus rotational and conventional digital subtraction angiography. *Radiology*. 2000;216:511–516.
81. Kuntz KM, Polak JF, Whitemore AD, Sillman JJ, Kent KC. Duplex ultrasound criteria for the identification of carotid stenosis should be laboratory specific. *Stroke*. 1997;28:339–342.

## Editorial Comment

### Funeral for a Friend

This editorial is not written by Elton John, and the funeral is not for Marilyn Monroe. We are neuroradiologists, and it is probably time to say farewell to diagnostic digital subtraction angiography (DSA) in patients with carotid artery stenosis.

Moniz,<sup>1</sup> a Portuguese neurologist, brought cerebral angiography to life in 1927, and since then, techniques have improved continuously up to ultrasoft catheters and high-resolution biplane angiography equipment. However, despite all these improvements, it is still risky to inject a contrast agent into the cerebral circulation.<sup>2</sup> We all are hopeful that visualization of supra-aortal vessels might be possible some day without any risk to the patient.

Ultrasound with its variants was a major step forward toward noninvasive imaging of the carotid bifurcation.<sup>3,4</sup> Depending on the person who did the examination, it became a perfect screening tool and replaced DSA for presurgical workup in those institutions in which experienced “ultrasounders” and vascular surgeons had the opportunity to work and learn together. However, it is highly observer dependent, and DSA remained the gold standard. As a consequence, we all perform many diagnostic angiographies in patients with internal carotid artery (ICA) stenosis who had at least 1 Doppler ultrasound examination previously.

In 1985, a *Science* article by Wedeen and colleagues<sup>5</sup> established the next milestone: Projective imaging of pulsatile flow was possible with MR, and it works without contrast agent injection. At that time, image quality was bad; temporal and spatial resolution was far beyond from being satisfactory. But since then, MR angiography (MRA) became an ultrafast, high-resolution imaging method. It still works without contrast agent injection (time-of-flight technique), but the faster variant is based on intravenous bolus injection of a paramagnetic agent. With the latter technique, supra-aortal vessels from the aortic arch to the circle of Willis can be visualized in a 10-second shot. Despite these fantastic technical possibilities, there is ongoing debate about the diagnostic power of MRA, and in many institutions, MRA is used as an add-on tool. During the first years of MRA, we all had a tendency to overestimate the degree of stenosis, but after a while, we learned to look at the images the right way. However, many scientific articles dealt with this overestimation problem, and neurologists and vascular surgeons, despite increasingly enjoying the image quality, had remaining doubts about the diagnostic power.

In the current issue of *Stroke*, Nederkoorn and his team present an excellent meta-analysis comparing MRA, duplex ultrasound (DUS), and DSA. In total, 62 articles were analyzed. MRA had a pooled sensitivity and specificity of

95% and 90% in detecting severe ICA stenosis. The discriminating power of MRA for the distinction of <70% versus 70% to 99% stenosis was significantly better than the power of DUS. Most MRA studies were based on non-contrast-enhanced techniques, but overall, the authors did not find a significant difference in diagnostic power between different MRA techniques. It was the same group that recently found that the mean difference between stenoses at MRA and DSA in corresponding projections was 0.4% (95% confidence interval, -2.0 to 2.7). If corresponding MRA and intraarterial DSA projections are compared, 3-dimensional time-of-flight MRA does not overestimate carotid stenosis.<sup>6</sup>

What is the conclusion? The authors are pretty cautious and state only that MRA has better discriminatory power than DUS in recognizing 70% to 99% stenosis and is a sensitive and specific test compared with DSA in the evaluation of carotid artery stenosis.

From a clinical point of view (and this is our interpretation), this could be translated as the following: We do not need diagnostic DSA in patients with carotid artery stenosis. DUS is already excellent; MRA is better. If MRA and DUS really leave anything open, CT angiography, specifically if multirow CT machines are available, is another excellent minimally invasive tool to visualize vessel pathology. Another future gimmick of MR imaging will become "plaque imaging" and with high-resolution techniques, which might give us totally new insights into the pathology of the vessel wall and the clinical impact of different types of ICA bifurcational disease. There will always be patients with contraindications to MRI, previously stented patients and probably some rare clinical situations (occlusion of ICA with ongoing ipsilateral transient ischemic attacks), that will allow us to do a DSA. Long et al<sup>7</sup> just reported that in France >60% of carotid endarterectomies are still based on DUS and DSA findings. Lack of access to MRA is the limiting factor. And this may be another circumstance justifying DSA in these patients.

However, for those who like to be part of the angio suite, it is much too early to retire. Interventional neuroradiology is growing rapidly. The International Subarachnoid Aneurysm Trial Collaborative Group just figured out that endovascular

therapy of ruptured intracranial aneurysms is better than clipping in terms of patient outcome.<sup>8</sup> Single-center experiences suggest that stenting of ICA stenosis might be at least equal to surgery. Currently, a couple of studies on the way are attempting to randomize patients into an endovascular and a surgical treatment arm. What will become more difficult is training people if they are not allowed to do diagnostic angiographies any more. But we have to manage this training problem the way that Nederkoorn and his colleagues managed to figure out what the right answer to an important question is. And they did a good job.

**Michael Forsting, MD, Guest Editor**

**Isabel Wanke, MD, Guest Editor**  
*Institute of Diagnostic and Interventional Radiology*  
*Department of Neuroradiology*  
*University of Essen*  
*Essen, Germany*

## References

1. Moniz E. L'encephalographie arterielle, son importance dans la localisation des tumeurs cerebrales. *Rev Neurol*. 1927;34:72-89.
2. Hankey GJ, Warlow CP, Molyneux AJ. Complications of cerebral angiography for patients with mild carotid territory ischemia being considered for carotid endarterectomy. *J Neurol Neurosurg Psychiatry*. 1990; 53:542-548.
3. Paulat K, Pauschinger P, Popp M, Schiebe M, Widder B. A new sensitive method for the quantification of internal carotid stenoses by means of ultrasound Doppler signal processing. *Cardiovasc Res*. 1985;19: 714-720.
4. Garth KE, Carroll BA, Sommer FG, Oppenheimer DA. Duplex ultrasound scanning of the carotid arteries with velocity spectrum analysis. *Radiology*. 1983;147:823-827.
5. Wedeen VJ, Meuli RA, Edelman RR, Geller SC, Frank LR, Brady TJ, Rosen BR. Projective imaging of pulsatile flow with magnetic resonance. *Science*. 1985;230:946-948.
6. Nederkoorn PJ, Elgersma OE, Mali WP, Eikelboom BC, Kappelle LJ, van der Graaf Y. Overestimation of carotid artery stenosis with magnetic resonance angiography compared with digital subtraction angiography. *J Vasc Surg*. 2002;36:806-813.
7. Long A, Lepoutre A, Corbillon E, Branchereau A, Kretz JG. Modalities of preoperative imaging of the internal carotid artery used in France. *Ann Vasc Surg* 2002;16:261-265.
8. Molyneux A, Kerr R, Stratton I, Sandercock P, Clarke M, Shrimpton J, Holman R, for the International Subarachnoid Aneurysm Trial (ISAT) Collaborative Group. International Subarachnoid Aneurysm Trial (ISAT) of neurosurgical clipping versus endovascular coiling in 2143 patients with ruptured intracranial aneurysms: a randomised trial. *Lancet* 2002; 360:1267-1274.